

Virtual Microscopy: Potential Applications in Medical Education and Telemedicine in Countries with Developing Economies

Paul Fontelo¹, Ernest DiNino², Krista, Johansen², Ashraf Khan², Michael Ackerman¹

¹Office of High Performance Computing and Communications,
Lister Hill National Center for Biomedical Communications, National Library of
Medicine, Bethesda, Maryland

²University of Massachusetts Medical School, Worcester, Massachusetts.

Address correspondence to: fontelo@nlm.nih.gov

Abstract

We evaluated the diagnostic accuracy of a virtual microscopy setup using surgical pathology specimens commonly encountered in a university hospital setting. The high quality images, Internet sharing and collaborative capability, interactivity, and ease of use suggested to us that this might have applications in countries with developing economies. We discuss the development process and its potential applications in medical education and telemedicine in countries with developing economies.

Introduction

A virtual microscope or a virtual slide simulates the experience of examining a glass slide under the microscope. Briefly, virtual microscopy involves digitizing a tissue specimen on a glass slide, processing and archiving the images on a server and viewing them on a monitor with a browser. The interactive manner by which images are viewed (panning, zooming in and out) mimics the experience of examining a glass slide under an optical microscope.

Virtual microscopy provides several advantages: 1) images of the entire specimen can be viewed on a monitor that allows many users to see the images without the need of a microscope. This promotes a collaborative environment and enhances patient case discussions that benefits users of the technology. 2) Digitized images can be archived on a network server that can be shared by many. Unusual, unique, and one-of-a-kind specimens such as small tissue biopsies, and other related patient material that cannot be duplicated or reproduced because of limited samples, can be used for teaching and training.

3) A permanent record of specimens can be prepared that might enhance the patient's electronic medical record. 4) In countries with developing economies (CDE), this may circumvent the requirement for microscopes and the associated challenge of maintaining them. It will add a valuable teaching resource for medical educators. This particular application is the focus of this report.

A potential disadvantage of virtual microscopy is the requirement for high bandwidth. In CDEs, this challenge can be resolved by disseminating digitized images through compact discs and other portable storage media. Once the image files are obtained, a local intranet server could allow medical students and students of allied health care schools, and health care personnel to view the images through Web browsers. Another disadvantage is that the initial cost of hardware to digitize microscopic glass slides might be unaffordable for a CDE. This challenge might be resolved by forming partnerships and other collaborative arrangements with medical schools and universities in developed countries, or through sharing of hardware among medical institutions in CDEs. Glass slides could be digitized using equipment in developed countries and distributed to users in developing countries.

This project was initiated with four goals in mind: 1) design and development of a virtual microscope; 2) create a Virtual Microscopy Web site¹ to archive digitized images; 3) evaluate diagnostic accuracy in virtual microscopy; 4) archive virtual slides in a local server and view them through an intranet. All of these goals were achieved.

Recent medical literature discuss the use of virtual slides and virtual microscopes in medical education.²⁻⁵ For example, the adoption of this technology has allowed the University of South Carolina School of Medicine to teach histology with good student and faculty acceptance. The successful implementation of virtual microscopy allowed the school to discontinue the recommendation of microscope rentals for students, although they did not discourage their use so medical students will learn how to use microscopes.² Current literature also documents applications in telemedicine, especially in telepathology and teledermatology.⁶⁻⁹

The high concordance between the diagnoses rendered on glass slides (gold standard) and virtual microscope indicate the high quality of images obtained. The high quality images, ease of use and Web accessibility suggested to us that virtual slides might be useful technology for medical education especially in low resource settings. Virtual slides can be shared through the Internet, or distributed through portable storage devices such as compact disks or digital videodisks, to geographic locations where the high bandwidth requirements for remote viewing on the Internet are not available. The virtual slides can then be archived on a local server and viewed using computers connected to a local network (intranet.)

We report our experience in developing a virtual microscope and discuss potential applications in CDEs.

Materials and Methods

Technical Equipment and Setup

An Olympus BX51 microscope was used. The images were captured using an Olympus DP70 12.5 megapixel digital color camera. The camera was connected to a PC Pentium 4 2.53 GHz computer with 1 gigabyte of random access memory. A Prior Scientific robotic stage system with a horizontal-vertical motorized controller was used to mechanically manipulate the movement of the slide on the stage. AnalySIS (Soft Imaging System Corp) image acquisition software, DP70-BSW-V1.2 capture and archiving software, and Microsuite ScopeView (Soft Imaging System Corp) microscope control software were used to capture the images.

Images were also digitized manually using an Olympus BX41 microscope with an OLY 750 analog camera, connected to a PC Pentium 1.3GHz computer with a graphics card. Serial, overlapping images of selected microscopic fields were captured. The single TIFF images were stitched together using Adobe Photoshop to create one large image and archived on the server in JPEG (Joint Photographic Experts Group) format.

Image Acquisition

Ten hematoxylin and eosin stained glass slides of commonly encountered general surgical pathology specimens in a medical center setting were selected for digitization. There was no patient identifying information on the glass slides. Two methods for image acquisition were employed. The first technique consisted of capturing images with a 20% overlap between contiguous fields of view. This method was used to acquire complete 4x images of the slides in the study. The camera was configured to acquire images at 640 x 480 pixels per image and the stage was programmed to acquire the entire tissue specimen. To provide additional cellular detail, selected areas in some specimens were scanned at higher magnification. Image acquisition was considered complete when every tissue specimen in its entirety was digitized at 4x; specimens necessitating higher power views for diagnosis were digitized in their entirety at 20x; and selected higher power images were acquired to demonstrate cellular detail.

Each image was save in the Tagged Image File Format (tiff), a lossless file compression format. PanaVue ImageAssembler software was used to "stitch" the individual 4x tiff images together to form a single large image. Depending upon specimen size, the total images stitched for each slide ranged from 72 and 90, and the size of the resulting 4x image montage between 49 and 62 megabytes.

Image Rendering on the Web

The stitched images (single tiff image of each specimen) were displayed on client Web browsers using Macromedia Flash and Zoomify software. Zoomify software partitioned the large image into multiple smaller tiled segments; each image was downloaded individually, then

dynamically reconstructed and displayed rapidly on the Web browser with the Flash plug-in.

A browser interface program was developed using JavaScript and PERL. A user login was required to access the server. Interactivity and microscope experience simulation allowed the user to remotely pan and zoom the slide as needed. A thumbnail image next to the large image provided navigation landmarks to orient the user. A form allowed study participants to type their diagnosis and comments. This form was then sent electronically for review and analysis.

Clinical Study Setup

Six pathology residents at various levels of training, and three pathology attending physicians agreed to participate in the study. The pathologists were each assigned a random login name and password. Participant information, such as names and training level were unknown to the study administrators. Information on the site of origin of each specimen and magnification power of images was provided with the image. Study participants were asked to comment on the level of confidence for each diagnosis and indicate factors that had a negative impact on their confidence level.

Results

Of the six pathology residents and three attending physicians who agreed to participate, only four residents and one attending physician completed the study. Reasons for nonparticipation varied, but the only one documented was a resident traveling in Eastern Europe who attempted to review the images using a 56-kilobit (kb) modem. The resident reported several attempts to review the images but was unsuccessful because of session timeouts. We tried to reproduce his experience by using a 56kb connection to the Internet from the same building where the server was located. Our results showed that a full-sized image required 5-13 minutes to display on the monitor completely. Each attempt to view a new field required approximately the same time. On the contrary, feedback from colleagues in CDE with broadband connections (DSL or cable modem connection) and our own experience with wireless local home networks internal to

broadband connections showed acceptable to very satisfactory viewing of Web archived images.

We initially embarked on manual digitization of images from a glass slide. Although this method was successful, the time and effort involved was enormous. It required one of the authors (ED) one week of 8-10 hour days to capture multiple images, stitch them together to create a composite image of a 3 x 5 mm specimen (Figure 1). Due to high requirement of time and effort, it was decided to continue the project using an automated image capture system. Ten glass slides were digitized and archived on a Web server. Digitizing 64 images at 4x required 5 ± 2 minutes; at 20x, 8 ± 2 minutes; and at 40x, 15 ± 5 minutes. Depending on specimen size, the total number of images digitized ranged from 72 and 90, and the single composite image between 49 megabytes and 62 megabytes. At 40x magnification, an order of magnitude greater number of images was required to capture the same area. Image processing required the manipulation of 1000 images or more, to create the single composite image of the entire specimen and a file size of one gigabyte or greater. This led to technical problems and computer system instability. Another difficulty encountered was that at higher magnifications, blank fields (no tissue in field of view) were encountered. These blank fields made proper image alignment difficult, which led to poor quality images.

Table 1 summarizes the diagnosis of the specimens used in the study and the types images digitized for each specimen. The need for additional images, the area selected, and the magnification power obtained from each specimen were subjective. The cervical ThinPrep slide was scanned only at 40x magnification, but the areas selected were subjective. Some slides required several attempts at digitizing section because earlier images were determined to be suboptimal for diagnosis.

Table 2 summarizes the overall study result. All participants correctly identified the underlying pathologic process, i.e., malignant tissue was called malignant, and benign as benign. The concordance between study diagnosis and reference diagnosis (based on glass slide) was 88%.

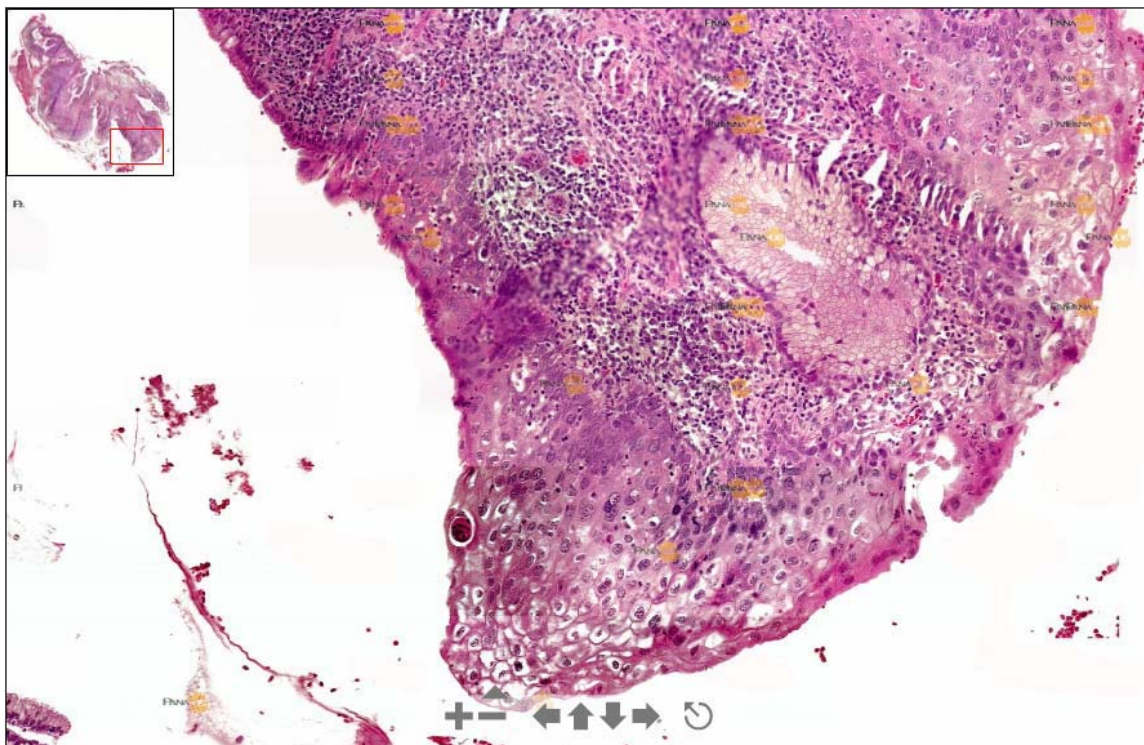


Figure 1. A composite image of a cervical biopsy specimen. The thumbnail image (above left) shows the orientation of the section of specimen magnified in this image. The triangular icon above the negative sign indicates that this image is approximately a 15% digital magnification of what a full-sized 20x image might look like

Specimens and images digitized for the study

Diagnosis	Digitized at 4X	Supplemental images	Digitized at 20X	Digitized at 40x
Thyroid, Medullary carcinoma	√	√ 10X		
Skin, Squamous cell carcinoma in-situ	√		√	
Lung, Squamous Cell Carcinoma	√	√ 20X		
Breast, Infiltrating Lobular Carcinoma	√		√	
Breast, Fibroadenoma	√	√ 10X		
Cervical Thin Prep, HSIL				√
Skin, Malignant Melanoma	√		√	
Skin, Metastatic Breast Carcinoma	√	√ 10X		
Endometrium, Mucinous carcinoma	√			
Thyroid, Papillary Carcinoma	√	√ 20X		

Table 1. Summary of the diagnosis of the specimens used in the study and the types images digitized for each specimen. The Cervical ThinPrep was digitized at 40x only.

Concordance between diagnosis and study participant's diagnosis

Diagnosis	Concordance with Reference Diagnosis (%)	Concordance with pathologic process (%)
Thyroid, Medullary carcinoma	4/5 (80%)	5/5 (100%)
Skin, Squamous cell carcinoma in-situ	5/5 (100%)	5/5 (100%)
Lung, Squamous Cell Carcinoma	4/5 (80%)	5/5 (100%)
Breast, Infiltrating Lobular Carcinoma	5/5 (100%)	5/5 (100%)
Breast, Fibroadenoma	5/5 (100%)	5/5 (100%)
Cervical Thin Prep, HSIL	5/5 (100%)	5/5 (100%)
Skin, Malignant Melanoma	5/5 (100%)	5/5 (100%)
Skin, Metastatic Breast Carcinoma	5/5 (100%)	5/5 (100%)
Endometrium, Mucinous carcinoma	1/5 (20%)	5/5 (100%)
Thyroid, Papillary Carcinoma	5/5 (100%)	5/5 (100%)
Concordance with Reference Diagnosis	44/50 (88%)	50/50 (100%)

Table 2. A summary of the overall study result. All pathologic processes were correctly identified (100%.) Concordance with reference diagnosis (glass slide diagnosis) was 88%. This change was attributed to variations in providing specific diagnosis according to cell type.

Discussion

Our experience suggests that a virtual slide can be created manually, but will require many hours of technical hands-on time. However, if only a small area of the specimen is selected, the time and effort required will be proportionately less. Images taken from small areas of the slide that show classic lesions can be selected. These limited sections in a glass slide can be easily digitized, and the captured images stitched together manually.¹² The resulting virtual slides may be adequate for illustrating medical

concepts and satisfactory for teaching. Manual digitization of glass slides will circumvent the necessity for an automated virtual microscope setup.

The advantage of the manual digitization method may be that hardware needed to capture images already exists in many medical schools. A microscope with a camera, an image capture board on a computer, and image stitching software would be sufficient to develop a

collection of images. These images can be archived on a network server, or distributed to students on CDs or other portable media. This technology is within the capability of many health care schools in countries with developing economies. Some examples of Web sites archiving manually created virtual microscopes can be found on the Internet.

Broadband connections are required for viewing virtual slides on the Internet, a setup unlikely to be encountered in countries with developing economies. However, a possible solution to this problem can be the creation of a local network using open source software and commercially available hardware. With an Apache Web server archiving digitized images, Web browsers with the appropriate plug-ins can be used to view the images and simulate a real-time broadband experience. The virtual slides may be prepared locally, or obtained through portable media distribution, such as compact disks.

In an automated system, our experience has shown that an entire specimen can be easily scanned in at 4x magnification using the technique described. A small specimen (<5mm) may require more than 100 images. With each images comprising 1 MB, image processing and stitching can be done quickly, with the final image (entire specimen) approximately 100MB in size or less.

Although each image sent to the client Web browser is small (less 20kb each), viewing through a 56kb modem was unsatisfactory because of session timeouts and prolonged image rendering. This is most likely due to service degradation brought about by simultaneous transmission of multiple images to the user's browser.

The unsatisfactory viewing experience with dialup connection, the most prevalent form of connectivity to the Internet in CDE implies that this is not a viable option. Images will need to be distributed via portable media. When locally available, these images could then be archived on a local server and viewed through the local network. Case studies can be developed using other patient material (radiographs, surgical specimens, etc) that can then be presented as an integrated case presentation. A problem-based learning module can be built around virtual microscopy.

Scanning an entire specimen at higher magnification is more difficult. Several issues arise when scanning at higher magnification, Digitizing images at 20 to 40X magnification entails many more images to capture the same area size. It may require manipulation of 1000 images or greater, with the entire specimen comprising a file size of a gigabyte or greater. This leads to significant problems in computer memory and system stability. Additionally, images obtained at 40X or 20X will likely have blank fields (no tissue in field of view.) These blank fields make proper image alignment difficult often leading to poor quality images.

Image preparation and archiving setup allows sending small tiled images (~ 20KB size) to the requesting client through their Web browser. This method enables on-demand zooming and panning for a more detailed view at higher resolution. When using broadband Internet connections (DSL, Cable, or high speed local area network), interactive viewing of images was smooth and seamless. Viewing images within an 802.11b wireless network inside a local area network connected to the Internet through cable or LAN was also satisfactory. In this networking environment, rapidly scanning the cytology slide (largest file in the archive) simulated the optical microscope experience closely.

Although the overall concordance (agreement between reference diagnosis from glass slides to that of virtual slides) was 88%, all pathologic processes were correctly identified (100%.) Malignant specimens were diagnosed as malignant; benign processes were all correctly identified. Most of the discrepancy was attributed to variations in providing the specific cell type of a case of mucinous carcinoma of the endometrium. Had we been less stringent with our criteria for concordance for this specimen, an agreement close to a 100% between reference and study diagnoses would have been obtained.

Virtual microscopy may be used also for telemedicine, especially in specialties that require high quality images such as telepathology, teleradiology, and teledermatology. These applications of virtual microscopy have been successfully deployed in developed countries.⁶⁻⁹ Applications in proficiency testing and quality assurance applications have been reported.¹⁰

We believe this is the first report that deals with virtual microscopy for CDE. Although the potential is great, hardware requirements will influence its dissemination as a tool for medical education. Open virtual microscope archives, such as that developed by the University of Basel

Acknowledgement

This work was done as part of an elective rotation by one of the authors (ED) at the Lister

References

[1] NLM Virtual Microscopy Web site:
<http://erie.nlm.nih.gov/~slide2go/>

[2] Blake CA, Lavoie HA, Millette CF. Teaching medical histology at the University of South Carolina School of Medicine: Transition to virtual slides and virtual microscopes. *Anat Rec.* 2003 Dec;275B(1):196-206.

[3] Heidger PM Jr, Dee F, Consoer D, Leaven T, Duncan J, Kreiter C. Integrated approach to teaching and testing in histology with real and virtual imaging. *Anat Rec.* 2002 Apr 15;269(2):107-12.

[4] Harris T, Leaven T, Heidger P, Kreiter C, Duncan J, Dick F. Comparison of a virtual microscope laboratory to a regular microscope laboratory for teaching histology. *Anat Rec.* 2001 Feb;265(1):10-4.

[5] Romer DJ, Yearsley KH, Ayers LW. Using a modified standard microscope to generate virtual slides. *Anat Rec.* 2003 May;272B(1):91-7

[6] Okada DH, Binder SW, Felten CL, Strauss JS, Marchevsky AM. "Virtual Microscopy" and the Internet as telepathology Consultation Tools: Diagnostic Accuracy in Evaluating Melanocytic Skin Lesions. *Amer J Dermatopath* 1999 Dec;21(6):525

[7] Costello SS, Johnston DJ, Dervan PA, O'Shea DG. Development and evaluation of the virtual pathology slide: a new tool in telepathology. *J Med Internet Res.* 2003 Apr-Jun;5(2):e11

[8] Steinberg DM, Ali SZ. Application of virtual microscopy in clinical cytopathology. *Diagn Cytopathol.* 2001 Dec;25(6):389-96.

[9] Molnar B, Berczi L, Diczhazy C, Tagscherer A, Varga SV, Szende B, Tulassay Z. Digital slide and virtual microscopy based routine and telepathology evaluation of routine gastrointestinal biopsy specimens. *J Clin Pathol.* 2003 Jun;56(6):433-8.

Department of Pathology¹¹ may be possible sources of virtual slides. Collaborative between academic centers in developed countries and educational institutions in countries with developing economies, or regional collaborations with other CDEs will further enhance its use.

Hill National Center for Biomedical Communications, National Library of Medicine, National Institutes of Health, Department of Health and Human Services.

[10] Marchevsky AM, Wan Y, Thomas P, Krishnan L, Evans-Simon H, Haber H. Virtual Microscopy as a Tool for Proficiency Testing in Cytopathology. *Arch Pathol Lab Med.* 2003;127:1320-1324

[11] Glatz-Krieger K, Glatz D, Mihatsch MJ. Virtual slides: high-quality demand, physical limitations, and affordability. *Hum Pathol.* 2003 Oct;34(10):968-74.

[12] Riley RS, Ben-Ezra JM, Massey D, Cousar J. The virtual blood film. *Clin Lab Med.* 2002 Mar;22(1):317-45.